

MORPHOMETRIC ANALYSIS OF SELLA TURCICA IN SOUTH INDIAN POPULATION-A STUDY IN DRY BONES

N. Mythily¹, A. Thenmozhi², S. Madhumalar³, K. Sangeetha¹, S. Deepa¹

Received : 10/10/2025
Received in revised form : 05/12/2025
Accepted : 22/12/2025

Keywords: *Sella Turcica, Morphology, Shapes of sella Turcica, Dry bones*

Corresponding Author:
Dr. K. Sangeetha
Email: drsangeethak@gmail.com

DOI: 10.47009/jamp.2026.8.1.211

Source of Support: Nil,
Conflict of Interest: None declared

Int J Acad Med Pharm
2026; 8 (1); 1113-1117



¹Assistant Professor, Department of Anatomy, Coimbatore Medical College, Coimbatore, Tamilnadu, India.

²Professor, Department of Anatomy, Krishnagiri Medical College, Krishnagiri, Tamilnadu, India.

³Assistant Professor, Department of Anatomy, Government Medical College, Pudukkottai, Tamilnadu, India.

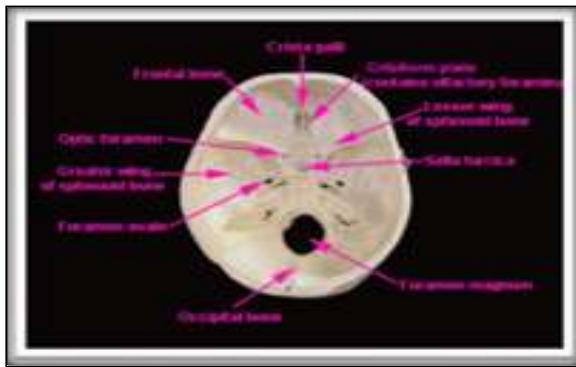ABSTRACT

Background: The Sella Turcica is part of the intracranial surface sphenoid bone lying behind the chiasmatic groove. The name Sella Turcica is derived from Latin meaning “Turkish saddle” (1693 Blanchard dictionary). The importance of Sella Turcica is its anatomical location in median position which is used for assessing the cephalometrics. The saddle shaped Sella is a part of middle cranial fossa. Sella Turcica is bounded in behind by the dorsum sellae and front by tuberculum sellae. The anterior and posterior clinoid processes are extensions of tuberculum sellae and dorsum sellae respectively. There are six different shapes of Sella Turcica namely normal, the anterior Wall is oblique, the floor of Sella with double contour, Sella Turcica with bridging, posterior part of Sella Turcica is irregular and the dorsum Sellae is Pyramidal in shape. Aim and objectives of the study is to measure and analyze morphological and morphometric parameters of Sella Turcica in dry bones. DRY Bone Study is Morphological types of Sella Turcica were observed in dry adult skull bones. The morphometric measurements like length, depth and antero posterior diameters of the Sella Turcica were taken in dry adult skull. **Materials and Methods:** Study design is Observational descriptive study. Study locale is South Indian population. **Result:** The Length, depth and anteroposterior diameter from dorsum sellae and tuberculum sellae. The shape of Sella Turcica in skull was noted and recorded. 30 human adult dry skulls with Sella Turcica were studied. The morphometric parameters of Sella Turcica were measured using vernier caliper in mm. Measurements like Length, Depth and Anteroposterior Diameters were taken and the mean values are calculated. The mean value of length of Sella Turcica in the present study was- 11.64mm. The mean value of depth of Sella Turcica in the present study was- 10.12mm. The mean value of anteroposterior diameter of Sella Turcica in the present study was- 13.60mm. **Conclusion:** In dry skull the length, depth and anteroposterior diameter were measured and found that anteroposterior diameter was larger than length There was significant difference in the measurements like length, depth and anteroposterior diameter of Sella Turcica which were taken from dry skull and its mean values have relationship with age. Sella Turcica one of the important landmark was mostly ignored but has great role been played by sella Turcica.

INTRODUCTION

The most inferior portion of the Sella Turcica is known as the hypophyseal fossa and contains the pituitary gland. Sella Turcica has a complex anatomy because of its relation with pituitary gland, internal carotid artery and the optic nerve. The Sella Turcica since located in middle cranial fossa is been more prone for tumors, vascular, developmental, endocrine disorders (Isolan et al., 2009).

There are six different shapes of Sella Turcica namely normal. The anterior Wall is oblique, the floor of Sella with double contour, Sella Turcica with bridging, posterior part of Sella Turcica is irregular and the dorsum Sellae is Pyramidal in shape.



Embryology of Sella Turcica: Developmentally, Sella Turcica develops from neural crest cells and paraxial mesoderm. It also plays a key role in development of frontonasal and maxillary areas by aiding in the emigration of neural crest cells. Development of pituitary gland is closely associated with the development of Sella Turcica but pituitary completes its development before Sella Turcica

Sella Turcica Significance in Forensic Medicine

The need for personal documentation is required in case of decay, skeletonization, damage of corpses, in consequence of fire, road traffic accidents, industrial accidents, natural disasters, in all the cases skeletal structure remains same that is it does not change its feature over time. Age, race, gender, can be identified from the skull so Sella Turcica an important part of skull may also be useful for personal finding during disasters-to establish bone

Significance of Sella turcica

Morphometric variation of Sella is related to variation in growth, it has also got important role in sex determination. The pituitary gland enlargement during the period of active growth causes Sella Turcica to enlarge. The variation in size of Sella Turcica possibly is related with some inborn or developed endocrine conditions like short stature

Shape of sell turcica

1. The shape of the Sella Turcica is not same in all individuals. Different authors recorded and classified the shape of Sella Turcica
2. Gorden and Bell classified shape of Sella Turcica as circular, oval, flat or saucer shaped.
3. Axelsson et al classified shapes of Sella Turcica as 6 main types as follows - normal shaped Sella Turcica, double contoured Sella, irregular notching in posterior part of Sella and pyramidal shaped dorsum Sella.

Various shapes of the sella turcica

A-F: Principal variations in sellar shape according to H.T.Martin:

- a. Round
 - b. Oval
 - c. Flat(shallow)
 - d. Deep
 - e. Quadrangular
 - f. Distorted, contracted
- G:"Sellar monstrosity" of Carstens.It lacks any real fossa; correspondingly, the hypophysis is inadequate. H-L: various types of bridging
 - M: Schneider's"pseudo-bridging."
 - N: Raab'svariant; tall, clumsy dorsum.
 - O: Fossa rounded and small, low wide dorsum, and posterior clinoid processes may be present or lacking.

MATERIALS AND METHODS

In Dry Bones: The dry base of skull bones was collected from Department of Anatomy. The shape of Sella Turcica was evaluated first then its length, depth, and anteroposterior measurements were taken using digital vernier caliper in mm. The length, depth and anteroposterior diameter were measured by following the method suggested by Silverman

Length: The length of Sella Turcica was measured from midpoint of tuberculum Sellae to mid-point of dorsum Sellae.

Depth: The depth was measured as deepest point of Sella and taken as right angle to length of Sella Turcica.

Anteroposterior Diameter: The anteroposterior diameters were measured from tuberculum Sellae to the floor of Sella Turcica as maximum transverse diameter.

Shape of Sella Turcica: In the shape of Sella Turcica it was perceived as normal, double contour of the floor, Oblique anterior wall, Pyramidal shape of dorsum Sellae, Irregularity in the posterior part of Sella Turcica.

The measurements were categorized in age wise distributions

- <19years
- 20to40years
- 41to60years
- 61to80years

The measurements were tabulated and mean length, mean depth and mean anteroposterior diameter was calculated. The shape of Sella Turcica was evaluated and recorded.

Mean length of Sella Turcica in X-Ray skull of Males and Females

Age/ Sex	Maximum value of Length in mm		Minimum value of Length in mm		Mean (±SD)	
	Male	Female	Male	Female	Male	Female
18-25	11.25	6.88	18.28	1.75	20.25	1.38
26-30	11.25	7.25	18.42	1.5	20.48	1.25
31-45	11	7.17	17.08	1.36	19.64	1.34

Dry Bones: Dry bones were collected from Department of Anatomy, PSGIMS&R.

Data collection

Dry bones: 40 Dry human skull bones with open calvarias from Department of Anatomy, PSG Institute of Medical Sciences and Research were included in this study. The bones were numbered from 1 to 20 and measured by using vernier caliper with accurate resolution of up to 0.01mm. All the measurements were recorded in the data sheet.

Exclusion criteria:

- Broken skull base bones
- Skull with gross pathology in Sella Turcica
- Skull with deformities and erosions in Sella Turcica
- Skull with Sella Turcica abnormalities or fusion of anterior, middle and posterior clinoid processes of Sella Turcica

Methodology

Study design: Observational descriptive study.

Study Locale: South Indian population.

Inclusion criteria

Dry bones:

- Normal adult human dry skull bones

Exclusion criteria:

Dry bones:

- Broken skull base bones
- Skull with gross pathology in Sella Turcica

S.No	Length in mm	Depth in mm	Anteroposterior diameter in mm	Shape
1	12.36	8.73	15.98	Normal
2	12.84	12.75	13.88	Oblique
3	15.32	9.78	16.17	Normal
4	12.07	12.06	15.29	Normal
5	15.93	10.45	19.05	Irregular
6	12.19	11.06	14.22	Oblique
7	11.75	10.08	15.3	Normal
8	12.69	12.04	17.17	Oblique
9	15.29	10.26	16.04	Pyramidal
10	15.52	10.1	16.15	Irregular
11	12.64	10.29	15.25	Normal
12	13.7	9.75	16.52	Normal
13	11.38	11.52	14.98	Oblique
14	13.72	8.33	14.29	Oblique
15	12.2	11.21	13.6	Normal
16	12.7	10.67	15.65	Normal
17	15.13	11.8	17.49	Normal
18	12.35	10.45	15.1	Pyramidal
19	10.94	8.73	15.7	Normal
20	11.24	10.37	14.43	Normal

Skull with deformities and erosions in Sella Turcica and Skull with Sella Turcica abnormalities or fusion of anterior, middle and posterior clinoid processes of Sella Turcica.

Dry Bone Study: Dry bones, digital sliding vernier caliper, Sony digital camera, computer, scanner, and printer

- Dry human skull bones with open calvarias from Department of Anatomy, PSG Institute of Medical Sciences and Research were included in this study. The bones were numbered from 1 to 60 and measured by using vernier caliper with accurate solution of up to 0.01mm. All the measurements were recorded in the data sheet.
- The dry base of skull bones was collected from Department of Anatomy. The shape of Sella Turcica was evaluated first then its length, depth, and anteroposterior measurements were taken using digital vernier caliper in mm.
- The length, depth and anteroposterior diameter were measured by following the method suggested by Silverman Length: The length of Sella Turcica was measured from midpoint of tuberculum Sellae to mid-point of dorsum Sellae.


Depth: The depth was measured as deepest point of Sella and taken as right angle to length of Sella Turcica.

Anteroposterior Diameter: The anteroposterior diameters were measured from tuberculum Sellae to the floor of Sella Turcica as maximum transverse diameter.

Shape of Sella Turcica: In the shape of Sella Turcica it was perceived as normal, double contour of the floor, Oblique anterior wall, Pyramidal shape of dorsum Sellae, Irregularity in the posterior part of Sella Turcica.

RESULTS

- The results of the above study were tabulated and analyzed in the following manner. The following measurements were taken and tabulated in the Sella Turcica.
- The Length, depth and anteroposterior diameter from dorsum sellae and tuberculum sellae.
- The shape of Sella Turcica in skull was noted and recorded.



Regarding the linear measurements of Sella Turcica there was notable difference in mean values of anteroposterior diameter, length and depth of Sella Turcica. Human adult dry skulls with Sella Turcica

were studied. The morphometric parameters of Sella Turcica were measured using vernier caliper in mm. Since the sex and age of the skull bones were not known it was not included in the study of dry skull bones. Measurements like Length, Depth and Anteroposterior Diameters were taken and the mean values are calculated and the results were tabulated in [Table 1]. The measurements of Sella Turcica in dry skull were as follows,

- The mean value of length of Sella Turcica in the present study was 11.64mm
- The mean value of depth of Sella Turcica in the present study was-10.12mm
- The mean value of anteroposterior diameter of Sella Turcica in the present study was- 13.60mm.

Shape of Sella Turcica	No of skulls	Percentage
Normal	25	75%
Oblique	13	15%
Irregular	11	5%
Pyramidal	11	5%
Double Contour, Bridging	-	0%

Mean Value of Measurements of Sella Turcica in Dry Skull

The statistical analysis showed that normal shape of Sella Turcica was found in 75% in and about 25% had variation in the morphology of the Sella Turcica; 15% of the subject had anterior wall variation, 5% had irregular dorsum sellae and pyramidal shaped Sella Turcica. In the present study there was no bridging and no double contour of Sella Turcica had been noticed in dry skull

Normal - Normal shape of Sella Turcica

Oblique - Oblique Anterior Wall

Irregular - Irregular Dorsum Sellae and

Pyramidal - Pyramidal Shaped Sella Turcica

Table : There was considerable difference in the incidents of various shapes in Sella Turcica in the present study when compared with other studies.

Author	Normal	Oblique Anterior Wall	Bridging	Double Contour	Notching	Pyramidal Shape
Priya Damodaran	56.8%	5%	6-16%	Nil	11%	17.64%
Present Study	75%	15%	Nil	Nil	5%	5%

DISCUSSION

morphometric measurements of sella Turcica were measured using vernier caliper.

The length, depth and anteroposterior diameter of Sella Turcica taken in dry skull bones were tabulated and compared with the previous studies.

The shape of Sella Turcica and the variation in it were observed and tabulated.

The mean length of Sella Turcica was 10.31mm in C.R.Ruiz's study, 10.59mm in the study of priyadamodaran, 18.45mm in Kevin, and 10.26mm in study by Tejendra, 72mm in the study by Daxa, 10.9mm in Yu.I.Pigokin study, 12mm in Amit Kumar study and in my present study (2019) it was 11.4mm. There was considerable difference in the studies of other authors with the present study.

Sella Turcica mean depth was 6.33mm in C.R.Ruiz, 9.23mm in the study by priya damodaran, 17.20mm in Kevin, and 7.65mm in study by Tejendra, 6.61mm in

the study by Daxa, 9.4mm in Yu.I.Pigokin study, 7mm in Amit Kumar study and in my present study (2019) it was 10.12mm. There was considerable difference in the studies of other authors with the present study.

The mean value of anteroposterior diameter Sella Turcica was, 10.76mm in the

study by priya damodaran, 21.14mm in Kevin, and 12.45mm in study by Tejendra, 11.64mm in the study by Daxa, 13.9 mm in Yu.I.Pigokin study, 13mm in Amit Kumar study and in my present study (2019) it was 13.60mm. There was considerable difference in the studies of other authors with the present study.

CONCLUSION

In dry skull the length, depth and anteroposterior diameter were measured and found that anteroposterior diameter was larger than length. There was significant difference in the measurements like length, depth and anteroposterior diameter of Sella Turcica which were taken from dry skull and its mean values have relationship with age. Sella Turcica one of the important landmark was mostly ignored but has great role been played by sella Turcica.

REFERENCES

1. Agrawal, G.N. and Newton, G.B., 1968. Radiological study of normal sella turcica in Indians. Journal of the Indian Medical Association, 51(7), pp.319-323.
2. Alkofide, E.A., 2007. The shape and size of the sella turcica in skeletal Class I, Class II, and Class III Saudi subjects. The European Journal of Orthodontics, 29(5), pp.457- 463.
3. Andredaki, M., Koumantanou, A., Dorotheou, D. and Halazonetis, D.J., 2007. A cephalometric morphometric study of the sella turcica. The European Journal of Orthodontics, 29(5), pp.449-456.

4. Axelsson, S., Storhaug, K. and Kjær, I., 2004. Post-natal size and morphology of the sella turcica in Williams's syndrome. *The European Journal of Orthodontics*, 26(6), pp.613-621.
5. Axelsson, S., Storhaug, K. and Kjær, I., 2004. Post-natal size and morphology of the sella turcica. Longitudinal cephalometric standards for Norwegians between 6 and 21 years of age. *The European Journal of Orthodontics*, 26(6), pp.597-604.
6. Boddeti, S.S., Varma, N.S., Sasidhar, Y.N., Ujwala, T., Navya, P. and Pradesh, A., 2016. The Size and the morphology of sella turcica in different skeletal patterns of south Indians: A lateral cephalogrametric study. *Int J Oral Health Med Res*, 3(1), pp.13-16.:
7. Camp, J.D., 1924. Normal and pathological anatomy of the sella turcica as revealed by roentgenograms. *Am J Roentgenol*, 12, pp.143-56.
8. Chaitanya, B., Pai, K.M. and Chhapparwal, Y., 2018. Evaluation of the effect of age, gender, and skeletal class on the dimensions of sella turcica using lateral cephalograms. *Contemporary clinical dentistry*, 9(2), p.195.
9. Chauhan, P., Kalra, S., Mongia, S.M., Ali, S. and Anurag, A., 2014. Morphometric analysis of sella turcica in North Indian population: a radiological study. *Int J Res Med Sci*, 2(2), pp.521-526.
10. Choi, W.J., Hwang, E.H. and Lee, S.R., 2001. The study of shape and size of normal sella turcica in cephalometric radiographs. *Imaging Science in Dentistry*, 31(1), pp.43-49.
11. Dalvi, V.T., Lingappa, A. and Sujatha, G.P., 2016. Age related dimensional changes of sella turcica observed in lateral cephalographs. *Journal of PEARLDENT*, 7(4), pp.15-26.
12. Daxa Kanjiya, B.J., 2015. Morphological Study of Sella Turcica in Gujarat State. *Medical Science*, 4(2).
13. Deepak, A., Pradeep, S. and Antony, S., 2018. Comparative morphometric analysis of sella turcica in males and females: A radiographic study. *Drug Invention Today*, 10.
14. Divya, S., Urala, A.S., Prasad, G.L. and Pentapati, K.C., 2018. Sella turcica bridging a diagnostic marker for impacted canines and supernumerary teeth. *Journal of International Oral Health*, 10(2), p.94.